



# EVALUATION OF PROSTATE IMAGING REPORTING AND DATA SYSTEM (PI-RADS) VERSION 2 FOR PROSTATE CANCER DETECTION: A RETROSPECTIVE SINGLE-CENTER STUDY

Lora Grbanović<sup>1</sup>, Lucija Kovačević<sup>1</sup>, Tomislav Kuliš<sup>2</sup>, Željko Kaštelan<sup>2,3</sup>, Marko Kralik<sup>1,3</sup>, Stjepan Ivandić<sup>4</sup> and Maja Prutki<sup>1,3</sup>

<sup>1</sup>Department of Radiology, University Hospital Centre Zagreb, Zagreb, Croatia

<sup>2</sup>Department of Urology, University Hospital Centre Zagreb, Zagreb, Croatia

<sup>3</sup>School of Medicine, University of Zagreb University of Zagreb, Zagreb, Croatia

<sup>4</sup>Sestre milosrdnice University Hospital Center, Zagreb, Croatia

**SUMMARY** – This retrospective study aimed to evaluate the performance of multiparametric MRI (mpMRI) interpreted according to the Prostate Imaging Reporting and Data System (PI-RADS) version 2 (v2) in detecting clinically significant prostate cancer (csPCa). The study included 62 patients with a clinical suspicion of prostate cancer who underwent mpMRI of the prostate interpreted according to the PI-RADS v2 between January 2018 and December 2018. Histopathologic findings were considered positive if csPCa was found; otherwise, clinical follow-up of at least 4 years was required to rule out the presence of csPCa. Diagnostic accuracy of PI-RADS v2 was calculated using score cutoffs of 3 and 4. Out of 114 lesions detected on mpMRI, 21 were identified as csPCa. The detection rates of PI-RADS scores 1-5 for detecting csPCa were 0%, 5.1%, 8.3%, 47.1%, and 87.5%, respectively. PI-RADS  $\geq 4$  cutoff yielded higher specificity (83.9%) and positive predictive value (93%) for detecting csPCa than PI-RADS  $\geq 3$  (specificity 41.9%; positive predictive value 26%), but exhibited lower sensitivity (71.4% versus 90.5%, respectively) and missed 28.6% of csPCa. In conclusion, better csPCa detection with PI-RADS v2 cutoff set at 3 comes at the cost of lower specificity and more unnecessary biopsies.

**Key words:** *prostatic neoplasms; multiparametric magnetic resonance imaging; PI-RADS*

## Introduction

Prostate cancer is the second most common cancer and the fifth leading cause of cancer death in men<sup>1</sup>. Early cancer detection is the most important strategy to enable cancer patients to have a better prognosis for

most solid cancers<sup>2</sup>. However, the importance of detecting prostate cancer at an early stage is debatable due to its heterogeneity<sup>3</sup>. The heterogeneity of prostate cancer results in phenotypes ranging from those that would not have become clinically significant during the patient's lifetime to more aggressive prostate cancers that require immediate treatment<sup>4</sup>. Widespread screening for prostate cancer with the PSA blood test remains controversial because it cannot reliably distinguish benign lesions and insignificant cancers from clinically significant cancers. Therefore, it leads

Correspondence to:

Lucija Kovačević

Department of Radiology, University Hospital Centre Zagreb

Kišpatićeva ul. 12, 10000 Zagreb

E-mail: kovacevic.lucija@gmail.com

to overdiagnosis and overtreatment and has little or no impact on prostate cancer mortality rate<sup>5</sup>. There is no general definition of clinically significant prostate cancer. However, according to the Prostate Imaging Reporting and Data System (PI-RADS) version 2 (v2), clinically significant prostate cancer is defined by a Gleason score  $\geq 7$  and/or tumor volume  $\geq 0.5$  cm<sup>3</sup> and/or positive extracapsular extension or seminal vesicle invasion<sup>6</sup>.

Elevated PSA levels and an abnormal rectal examination raise suspicion of prostate cancer and serve as an indication for prostate biopsy<sup>7</sup>. A systematic 10-12 core biopsy performed transrectally under ultrasound guidance is the standard for the diagnosis of prostate cancer<sup>8,9</sup>. Prostate ultrasound has low sensitivity for detecting small prostate cancers, making systemic 12-core transrectal ultrasound (TRUS) guided biopsy prone to sampling errors<sup>10-12</sup>. Therefore, the standard diagnostic approach to prostate cancer detection may lead to overdiagnosis and overtreatment of indolent prostate cancers and may miss clinically significant cancers, resulting in treatment delays.

In the last decade, the use of multiparametric MRI (mpMRI) has been encouraged in the detection of clinically significant prostate cancer because it improves diagnostic accuracy and may therefore reduce the proportion of patients with elevated PSA levels who require biopsy<sup>5,13</sup>. It is the best imaging modality for prostate cancer detection, grading, staging, and targeted biopsy guidance<sup>14</sup>.

The Prostate Imaging Reporting and Data System (PI-RADS) is the product of a collaboration of the American College of Radiology (ACR), the European Society of Urogenital Radiology (ESUR), and the AdMeTech Foundation, designed to standardize image acquisition techniques and interpretation of prostate mpMRI<sup>6,15</sup>. PI-RADS version 2 categorizes the likelihood of clinically significant prostate cancer on magnetic resonance imaging into five scores with increasing probability of clinically significant prostate cancer being present. PI-RADS v2 scoring has been shown to correlate with the Gleason score, which has a pivotal role in prostate cancer management<sup>16</sup>. As a result of improved diagnostic performances, the use of the PI-RADS v2 score has been recommended in patients with suspected cancer in treatment-naïve prostate glands since 2015<sup>17</sup>.

This study aimed to evaluate the performances of multiparametric MRI interpreted with PI-RADS v2

scores in detecting clinically significant prostate cancer.

## Methods

This single-center retrospective study was approved by the institutional review board, and the requirement for informed consent was waived. The hospital information system was reviewed for consecutive patients who underwent mpMRI of the prostate between January 2018 and December 2018 at the University Hospital Centre Zagreb. Only patients who underwent mpMRI of the prostate because of clinically suspected prostate cancer were included in the study. Patients who received prior treatment for prostate cancer were excluded from the study, as well as patients under active surveillance for prostate cancer, patients lost from follow-up, patients with histopathological reports not available, and patients with poor image quality of the prostate mpMRI. The patient selection process is summarized in **Figure 1**.

All patients were scanned between January 2018 and December 2018 in a 3T MR scanner (Prisma Fit, Siemens, Erlangen, Germany) using a phased-array surface coil. Following the acquisition of three plane localizer images, T2-weighted turbo spin-echo images were acquired in three orthogonal planes (sagittal, axial, and coronal), with the following scan parameters: repetition time 4130–6620 ms, echo time 91 or 101 ms, slice thickness 3 mm, interslice gap 0.3 mm, matrix 320x320 or 320x304, field of view 18 cm or 20 cm. To assess lymph nodes, an axial T1-weighted turbo spin-echo sequence was acquired with the following scan parameters: repetition time 415 ms, echo time 9 ms, slice thickness 5 mm, interslice gap 1.5 mm, matrix 256x240, field of view 32 cm.

Axial T2-weighted turbo spin-echo with short tau inversion recovery fat suppression (STIR) images of the whole pelvis were acquired using the following parameters: repetition time 6180 ms, echo time 57 ms, slice thickness 6 mm, interslice gap 3 mm, matrix 384x269, field of view 44.4 cm. Axial diffusion-weighted images were acquired using the following imaging parameters: b values of 0, 500, 1500, and 2000 s/mm<sup>2</sup>, repetition time 4100 ms, echo time 76 ms, slice thickness 3 mm, interslice gap 0.6 mm, matrix 114x114, field of view 20 cm. Apparent diffusion coefficient (ADC) maps were automatically constructed on a pixel-by-pixel basis. Axial dynamic contrast-enhanced images were acquired using a

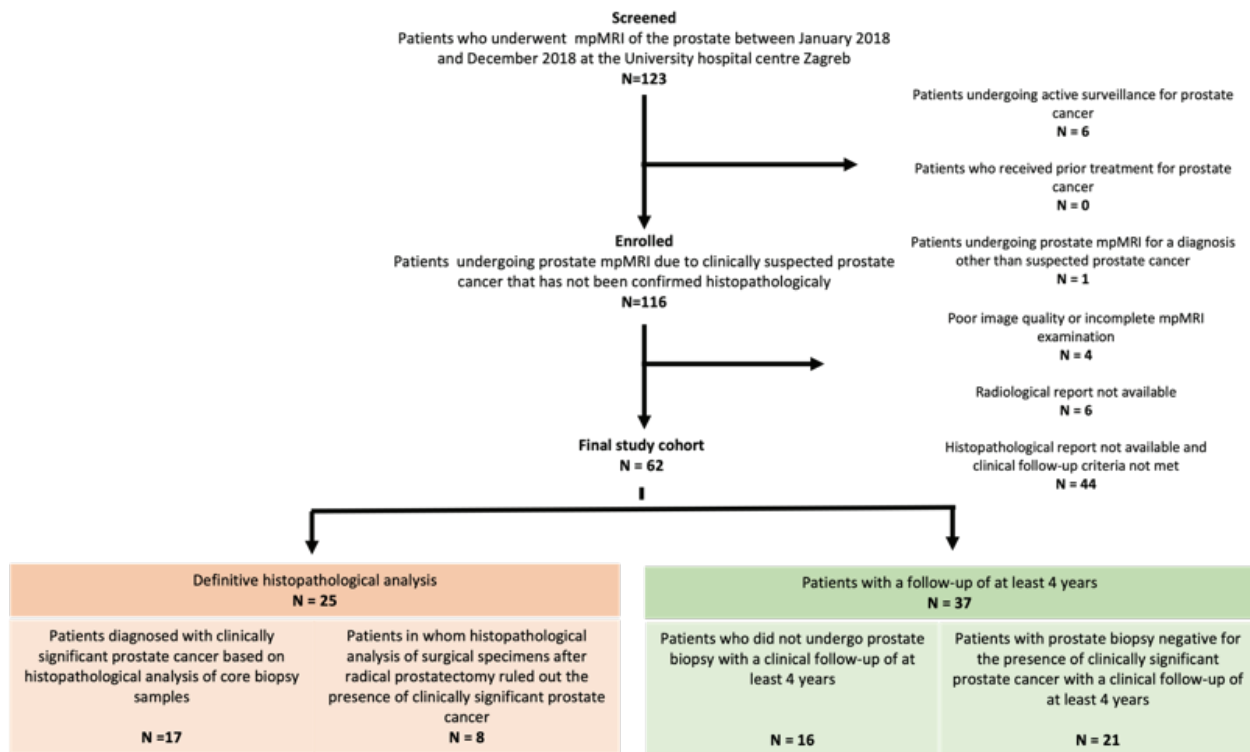


Figure 1. Flow chart of the patient selection process.

T1-weighted volumetric interpolated breath-hold examination (VIBE) sequence with the following imaging parameters: repetition time 3.11 ms, echo time 1.19 ms, slice thickness 3 mm, interslice gap 0 mm, matrix 224x101, field of view 32 cm. The dynamic acquisition consisted of one precontrast series and subsequent 50 postcontrast series performed after intravenous administration of gadoterate meglumine (Dotarem®, Guerbet, France) with a dose of 0.2 mL/kg body weight at a concentration of 0.5 mmol/L.

Radiological reports were reviewed for the presence of PI-RADS v2 lesion categorization.

In the patients who underwent biopsy, both targeted and systematic biopsy were performed using a 18G biopsy needle and an ultrasound station (Flex Focus 500, BK Medical, Denmark) with an ultrasound probe (8818, BK Medical, Denmark). All biopsies were performed in the lithotomy position, using a periprostatic block with 2% lidocaine and an end-fire transrectal probe. Targeted biopsies were performed using cognitive fusion technique with 6 cores divided in up to two leading lesions on the mpMRI and were followed by standard 12-core systematic biopsy. The analysis of the samples and assignment of Gleason scores, when

applicable, were performed by expert genitourinary pathologists.

Histopathological reports of biopsy specimens were reviewed for the presence of clinically significant prostate cancer in the patients who underwent biopsy after MRI. Clinically significant prostate cancer was defined according to PI-RADS v2 by having a Gleason score  $\geq 7$  on pathology/histology, and/or tumor volume  $\geq 0.5$  cm<sup>3</sup>, and/or extraprostatic extension<sup>6</sup>.

At least 4 years of follow-up for patients who did not undergo prostate biopsy and patients with a negative biopsy was required to exclude clinically significant prostate cancer. A subset of patients underwent prostatectomy during the follow-up, and their histopathological reports were reviewed as well.

Clinically significant prostate cancer detection rates were determined for each PI-RADS v2 category. Measures of diagnostic accuracy of PI-RADS v2 with cutoff values of score 3 and 4 for the detection of clinically significant prostate cancer were calculated.

## Results

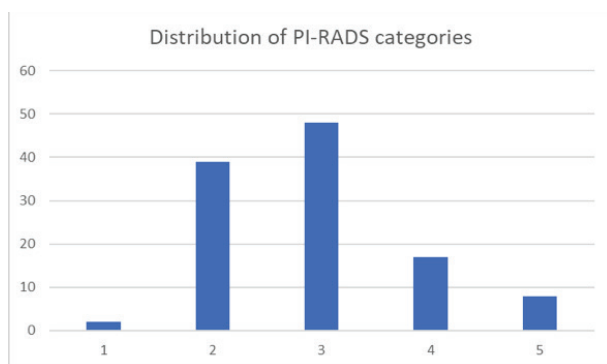
After the selection process, the study included 62 patients with a clinical suspicion of prostate cancer

who underwent mpMRI of the prostate between January 2018 and December 2018 and had an available radiological report. Patient characteristics are presented in **Table 1**.

*Table 1. Characteristics of patients included in the study (PSA – Prostate-specific antigen)*

Age, years, mean (range)		64,8 (44-78)
Prostate volume, mL, mean (range)		86,5 (29-264)
PSA level, ng/mL, mean (range)		10,4 (2-48)
Prior biopsy, n	0	7 (11.3%)
	1	26 (41.9%)
	2	16 (25.8%)
	≥3	13 (21%)

All radiological reports were written by one of two radiologists, each with more than 15 years of genitourinary imaging experience, who assigned a PI-RADS v2 score to each lesion detected. Lesions were detected in all 62 patients who underwent MRI. A total of 114 lesions were detected and assigned a PI-RADS score. The majority of patients (27, 43.5%) had two lesions that were detectable on mpMRI, 23 (37.1%) had 1 lesion, and 12 (19.4%) had 3 or more lesions. In total, there were 2 lesions with a PI-RADS score of 1, 39 lesions with a PI-RADS score of 2, 48 lesions with a PI-RADS score of 3, 17 lesions with a PI-RADS score of 4, and 8 lesions with a PI-RADS score of 5 (**Figure 2**).



*Figure 2. Distribution of PI-RADS categories.*

After mpMRI, the majority of patients were referred for biopsy (38, 61.3%). Prostate biopsy revealed 19 clinically significant cancers in 17 patients. During the follow-up, 2 additional clinically significant prostate cancers were detected in 2 patients. In the first patient, a PI-RADS 3 lesion was identified on MRI and subsequent biopsy revealed a low-grade prostate cancer (Gleason 6). The patient underwent a prostatectomy 16 months after the MRI, and histopathological analysis identified a clinically significant cancer (Gleason 7). In the second patient, who had a PI-RADS 4 lesion on MRI, the initial biopsy performed at an outside institution was negative. However, a rebiopsy performed 19 months after the MRI revealed a clinically significant (Gleason 7) prostatectomy.

Eight patients (12.9%) underwent prostate surgery for reasons unrelated to potential malignant disease. Accordingly, all histopathological findings were negative for prostate cancer.

The detection rates of clinically significant prostate cancer in biopsy specimens for PI-RADS scores 1, 2, 3, 4, and 5 were 0% (0/2), 5.1% (2/39), 8.3% (4/48), 47.1% (8/17), and 87.5% (7/8), respectively.

Measures of diagnostic accuracy of PI-RADS score for the detection of clinically significant prostate cancer were separately calculated for score cutoffs of 3 and 4 and are listed in **Table 2**.

*Table 2. Measures of diagnostic accuracy of PI-RADS V2 for the detection of clinically significant prostate cancer (PPV – positive predictive value, NPV – negative predictive value)*

PI-RADS	Sensitivity	Specificity	PPV	NPV	Accuracy
≥3	90.5%	41.9%	26%	95.1%	50.9%
≥4	71.4%	89.3%	60%	93%	86%

## Discussion

Our study findings confirm the usefulness of the PI-RADS v2 score for detecting clinically significant prostate cancer. The implementation of this valuable tool enables healthcare providers to make informed decisions regarding further diagnostics and management of tumors with a high potential for progression and propagation, while simultaneously avoiding over-treatment of indolent tumors.



As expected, the detection rate of clinically significant prostate cancer increased with increasing PI-RADS score. The detection rate of PI-RADS 1 and 2 score was 0% and 5.1%, respectively, indicating a low probability of clinically significant prostate cancer. In contrast, PI-RADS scores of 4 and 5 exhibited higher detection rates of 47.1% and 87.5%, respectively. These results are consistent with the previous studies and show a close resemblance to the study by Cash *et al.*, where the detection rate was 46.1% for PI-RADS 4 and 84.6% for PI-RADS 5<sup>18-23</sup>.

It has been reported that even expert radiologists can miss 15-30% of clinically significant cancers on mpMRI<sup>24</sup>. Even though the detection rate of clinically significant cancer for PI-RADS score 2 in this study was slightly below the data range of the previously published studies (5.1% versus 5.6%), it is important to investigate the potential causes of the failure to recognize such lesions as suspicious<sup>18,20-22</sup>.

In this study, both false negative lesions were located in the transition zone of the prostate. The previous studies have reported variable performance of multiparametric MRI (including T2-weighted, diffusion-weighted, and dynamic contrast-enhanced imaging) for the detection of transition zone cancer<sup>25</sup>. Detecting cancer in the transition zone of the prostate on MRI can pose a challenge due to the presence of benign prostatic hyperplasia (BPH) which may have a low-signal intensity on T2-weighted imaging (T2WI) similar to cancer, as well as an overlap of apparent diffusion coefficient (ADC) values with cancer<sup>26,27</sup>. Dynamic contrast-enhanced (DCE) imaging is also of limited value in detecting transition zone prostate cancer due to the high vascularity of benign prostatic hyperplasia<sup>27</sup>.

The review of the radiological reports indicated that the changes implemented in the PI-RADS v2.1 classification would increase the overall PI-RADS assessment category of these two lesions from 2 to 3, based on the DWI score of 4<sup>28</sup>.

Considering the presence of multiple lesions in the prostate of both patients, some with a PI-RADS score of 3, it is also possible that an inadvertent error in the biopsy site or marking of the biopsy samples may have led to false positive results for PI-RADS 2 lesions and false negative results for PI-RADS 3 lesions.

Using the threshold of PI-RADS 3, which denotes equivocal presence of clinically significant prostate cancer, yielded a high sensitivity and NPV of 91%

and 95%, respectively, which is in concordance with the previous studies that have reported sensitivities between 82% and 100%, and slightly above the reported range for NPV of 55-91%<sup>29-33</sup>. However, specificity, PPV, and accuracy were lower (41% versus reported range of 0-84%, 26% versus reported range of 45-85%, and 51% versus reported range of 65-85%, respectively), implying that although the cutoff value of PI-RADS 3 is effective in excluding clinically significant prostate cancer, it is more likely to produce false positive results<sup>29-33</sup>. It is our tendency to attribute the higher proportion of false-negative lesions in the PI-RADS 3 category to the caution of radiologists.

On the other hand, the sensitivity for the cutoff value of PI-RADS 4, indicating a lesion with high-risk for clinically significant prostate cancer, was lower than that of the cutoff of PI-RADS 3 (71% versus 91%). The specificity and PPV were higher for cutoff of PI-RADS 4 (89% versus 41% and 60% versus 26%, respectively), and NPV was similar (95% for PI-RADS 3 and 93% for PI-RADS 4). With the cutoff of PI-RADS 4, our results are consistent with the previous research, in which sensitivity, specificity, PPV, and NPV ranged between 32-100%, 7-96%, 67-82%, and 40-100%, respectively<sup>17,30,33,34</sup>, except for the accuracy of 86%, which was above the previously reported range of 65-68%. These results indicate that while the use of the cutoff value of PI-RADS 4 yields higher specificity for the detection of the clinically significant prostate cancer than the use of the cutoff value of PI-RADS 3, it may miss a considerable proportion of cases – specifically 6 out of 21 cases (28.6%) in our study, which should not be disregarded.

Transrectal ultrasound (TRUS)-guided biopsy of the prostate is a commonly employed diagnostic procedure for the detection of prostate cancer, but was shown to have a sensitivity of only 48% for detecting clinically significant prostate cancer, which was the reason we decided on an additional follow-up period for the patients with a negative biopsy<sup>35</sup>. In this study, two additional cases of clinically significant cancer were identified during the 4-year follow-up period. The first patient's PI-RADS 3 lesion, initially diagnosed as a low-grade cancer, was reclassified as a clinically significant cancer following prostatectomy performed 16 months after the MRI, and a PI-RADS 4 lesion in the other patient negative on the initial biopsy was confirmed to be a clinically significant cancer on repeated biopsy performed 19 months after the MRI.

The authors of the previous study have concluded that the risk of progression among prostate cancers with a Gleason score of 6 within the 3-year period is relatively low, and that in most cases an upgrade of a Gleason score within a shorter time interval is more likely to be a consequence of insufficient sampling at the first biopsy than true disease progression<sup>36</sup>. Based on our understanding, it is likely that the same holds true for the subsequently detected clinically significant cancers in this study. The detection of clinically significant prostate cancers can be improved by implementing transperineal template prostate-mapping (TTPM) biopsy, which has previously shown a sensitivity of 78% to 85%<sup>37</sup>.

Two key advantages of this study were utilization of clinical follow-up data, in addition to histopathologic findings, to exclude clinically significant prostate cancer, and use of 3T MRI findings to enhance precision. The drawbacks of our study included its retrospective nature and small sample size. Furthermore, each report was created by a single radiologist, and there was no assessment of inter-reader agreement. In order to expand upon the findings in this study, future studies should employ a prospective multi-center design with a larger sample size and include a measurement of inter-reader agreement.

In conclusion, the PI-RADS v2 score is useful for the detection of clinically significant prostate cancer. The specificity and positive predictive value for the PI-RADS 4-5 categories are better than PI-RADS 3-5. However, the percentage of missed carcinomas using the PI-RADS cutoff of 4 is not insignificant. The most effective detection of clinically significant prostate cancers is achieved with the PI-RADS cutoff value of 3, but at the expense of lower specificity. This may potentially lead to a greater number of invasive diagnostic procedures and associated complications. Finally, this study suggests that PI-RADS 3-5 lesions should be monitored for at least two years despite benign biopsy results.

#### Acknowledgments:

Lora Grbanović: Nothing to disclose.  
 Lucija Kovačević: Nothing to disclose.  
 Dr. sc. Tomislav Kuliš: Nothing to disclose.  
 Academician Željko Kaštelan: Nothing to disclose.  
 Dr. sc. Marko Kralik: Nothing to disclose.  
 Stjepan Ivandić: Nothing to disclose.  
 Prof. Dr. sc. Maja Prutki: Nothing to disclose.

#### References

- Sung H, Ferlay J, Siegel RL, Laversanne M, Soerjomataram I, Jemal A, et al. Global Cancer Statistics 2020: GLOBOCAN Estimates of Incidence and Mortality Worldwide for 36 Cancers in 185 Countries. *CA Cancer J Clin.* 2021 May;71(3):209-49.
- Pinsky PF. Principles of Cancer Screening. *Surg Clin North Am.* 2015 Oct;95(5):953-66. doi: 10.1016/j.suc.2015.05.009.
- Mishra SC. A discussion on controversies and ethical dilemmas in prostate cancer screening. *J Med Ethics.* 2020 Jul 6;medethics-2019-105979. doi: 10.1136/medethics-2019-105979.
- Tolkach Y, Kristiansen G. The Heterogeneity of Prostate Cancer: A Practical Approach. *Pathobiology.* 2018;85(1-2):108-16. doi: 10.1159/000477852.
- Bradley SH, Funston G, Jones D, Watson J. Diagnosing prostate cancer in asymptomatic patients. *BMJ.* 2022;377:e071076. doi:10.1136/bmj-2022-071076.
- Weinreb JC, Barentsz JO, Choyke PL, Cornud F, Haider MA, Macura KJ, et al. PI-RADS Prostate Imaging - Reporting and Data System: 2015, Version 2. *Eur Urol.* 2016 Jan;69(1):16-40. doi: 10.1016/j.eururo.2015.08.052.
- Matlaga BR, Eskew LA, McCullough DL. Prostate biopsy: indications and technique. *J Urol.* 2003 Jan;169(1):12-9. doi: 10.1016/S0022-5347(05)64024-4.
- Moe A, Hayne D. Transrectal ultrasound biopsy of the prostate: does it still have a role in prostate cancer diagnosis? *Transl Androl Urol.* 2020 Dec;9(6):3018-3024. doi: 10.21037/tau.2019.09.37.
- Baco E, Rud E, Eri LM, Moen G, Vlatkovic L, Svinland A, et al. A Randomized Controlled Trial To Assess and Compare the Outcomes of Two-core Prostate Biopsy Guided by Fused Magnetic Resonance and Transrectal Ultrasound Images and Traditional 12-core Systematic Biopsy. *Eur Urol.* 2016 Jan;69(1):149-56. doi: 10.1016/j.eururo.2015.03.041.
- Bjurlin MA, Mendhiratta N, Wysock JS, Taneja SS. Multiparametric MRI and targeted prostate biopsy: Improvements in cancer detection, localization, and risk assessment. *Cent European J Urol.* 2016;69(1):9-18. doi: 10.5173/cej.2016.734.
- Walker SM, Mehralivand S, Harmon SA, Sanford T, Merino MJ, Wood BJ. Prospective Evaluation of PI-RADS Version 2.1 for Prostate Cancer Detection. *AJR Am J Roentgenol.* 2020 Sep 2:1-6. doi: 10.2214/AJR.19.22679.
- King CR, Long JP. Prostate biopsy grading errors: a sampling problem? *Int J Cancer.* 2000 Dec 20;90(6):326-30. doi: 10.1002/1097-0215(20001220)90:6<326::aid-ijc3>3.0.co;2-j.
- Zhen L, Liu X, Yegang C, Yongjiao Y, Yawei X, Jiaqi K, et al. Accuracy of multiparametric magnetic resonance imaging for diagnosing prostate Cancer: a systematic review and meta-analysis. *BMC Cancer.* 2019 Dec 23;19(1):1244. doi: 10.1186/s12885-019-6434-2.
- Wibulpolprasert P, Raman SS, Hsu W, Margolis DJA, Asvadi NH, Khoshnoodi P, et al. Detection and Localization of Prostate Cancer at 3-T Multiparametric MRI Using PI-RADS Segmentation. *AJR Am J Roentgenol.* 2019 Jun;212(6):W122-W131. doi: 10.2214/AJR.18.20113.
- Steiger P, Thoeny HC. Prostate MRI based on PI-RADS version 2: how we review and report. *Cancer Imaging.* 2016 Apr 11;16:9. doi: 10.1186/s40644-016-0068-2.

16. Daun M, Fardin S, Ushinsky A, Batra S, Nguyentat M, Lee T, et al. PI-RADS Version 2 Is an Excellent Screening Tool for Clinically Significant Prostate Cancer as Designated by the Validated International Society of Urological Pathology Criteria: A Retrospective Analysis. *Curr Probl Diagn Radiol.* 2020 Nov-Dec;49(6):407-11. doi: 10.1067/j.cpradiol.2019.06.010.
17. Kasel-Seibert M, Lehmann T, Aschenbach R, Guettler FV, Abubrig M, Grimm MO. Assessment of PI-RADS v2 for the Detection of Prostate Cancer. *Eur J Radiol.* 2016 Apr;85(4):726-31. doi: 10.1016/j.ejrad.2016.01.011.
18. Cash H, Maxeiner A, Stephan C, Fischer T, Durmus T, Holzmann J, et al. The detection of significant prostate cancer is correlated with the Prostate Imaging Reporting and Data System (PI-RADS) in MRI/transrectal ultrasound fusion biopsy. *World J Urol.* 2016 Apr;34(4):525-32. doi: 10.1007/s00345-015-1671-8.
19. Hofbauer SL, Maxeiner A, Kittner B, Heckmann R, Reimann M, Wiemer L, et al. Validation of Prostate Imaging Reporting and Data System Version 2 for the Detection of Prostate Ca5ncer. *J Urol.* 2018 Oct;200(4):767-73. doi: 10.1016/j.juro.2018.05.003.
20. Barkovich EJ, Shankar PR, Westphalen AC. A Systematic Review of the Existing Prostate Imaging Reporting and Data System Version 2 (PI-RADSV2) Literature and Subset Meta-Analysis of PI-RADSV2 Categories Stratified by Gleason Scores. *AJR Am J Roentgenol.* 2019 Apr;212(4):847-54. doi: 10.2214/AJR.18.20571.
21. Mehralivand S, Bednarova S, Shih JH, Mertan FV, Gaur S, Merino MJ, et al. Prospective Evaluation of PI-RADS™ Version 2 Using the International Society of Urological Pathology Prostate Cancer Grade Group System. *J Urol.* 2017 Sep;198(3):583-90. doi: 10.1016/j.juro.2017.03.131.
22. Mertan FV, Greer MD, Shih JH, George AK, Kongnyuy M, Muthigi A. Prospective Evaluation of the Prostate Imaging Reporting and Data System Version 2 for Prostate Cancer Detection. *J Urol.* 2016 Sep;196(3):690-6. doi: 10.1016/j.juro.2016.04.057.
23. Thai JN, Narayanan HA, George AK, Siddiqui MM, Shah P, Mertan FV, et al. Validation of PI-RADS Version 2 in Transition Zone Lesions for the Detection of Prostate Cancer. *Radiology.* 2018 Aug;288(2):485-91. doi: 10.1148/radiol.2018170425.
24. Chatterjee A, He D, Fan X, Antic T, Jiang Y, Eggen S, et al. Diagnosis of Prostate Cancer by Use of MRI-Derived Quantitative Risk Maps: A Feasibility Study. *AJR Am J Roentgenol.* 2019 Aug;213(2):W66-W75. doi: 10.2214/AJR.18.20702.
25. Rosenkrantz AB, Kim S, Campbell N, Gaing B, Deng FM, Taneja SS. Transition zone prostate cancer: revisiting the role of multiparametric MRI at 3 T. *AJR Am J Roentgenol.* 2015 Mar;204(3):W266-72. doi: 10.2214/AJR.14.12955.
26. Hoeks CM, Hambroek T, Yakar D, Hulsbergen-van de Kaa CA, Feuth T, Witjes JA, et al. Transition zone prostate cancer: detection and localization with 3-T multiparametric MR imaging. *Radiology.* 2013 Jan;266(1):207-17. doi: 10.1148/radiol.12120281.
27. Gholizadeh N, Greer PB, Simpson J, Goodwin J, Fu C, Lau P, et al. Diagnosis of transition zone prostate cancer by multiparametric MRI: added value of MR spectroscopic imaging with sLASER volume selection. *J Biomed Sci.* 2021 Jul 19;28(1):54. doi: 10.1186/s12929-021-00750-6.
28. Scott R, Misser SK, Cioni D, Neri E. PI-RADS v2.1: What has changed and how to report. *SA J Radiol.* 2021 Jun 1;25(1):2062. doi: 10.4102/sajr.v25i1.2062.
29. Baldisserotto M, Neto EJ, Carvalhal G, de Toledo AF, de Almeida CM, Cairoli CE, et al. Validation of PI-RADS v.2 for prostate cancer diagnosis with MRI at 3T using an external phased-array coil. *J Magn Reson Imaging.* 2016 Nov;44(5):1354-9. doi: 10.1002/jmri.25284.
30. Rastinehad AR, Waingankar N, Turkbey B, Yaskiv O, Sonstegard AM, Fakhoury M, et al. Comparison of Multiparametric MRI Scoring Systems and the Impact on Cancer Detection in Patients Undergoing MR US Fusion Guided Prostate Biopsies. *PLoS One.* 2015 Nov 25;10(11):e0143404. doi: 10.1371/journal.pone.0143404.
31. Washino S, Okochi T, Saito K, Konishi T, Hirai M, Kobayashi Y, et al. Combination of prostate imaging reporting and data system (PI-RADS) score and prostate-specific antigen (PSA) density predicts biopsy outcome in prostate biopsy naïve patients. *BJU Int.* 2017 Feb;119(2):225-33. doi: 10.1111/bju.13465.
32. Zhao C, Gao G, Fang D, Li F, Yang X, Wang H, et al. The efficiency of multiparametric magnetic resonance imaging (mpMRI) using PI-RADS Version 2 in the diagnosis of clinically significant prostate cancer. *Clin Imaging.* 2016 Sep-Oct;40(5):885-8. doi: 10.1016/j.clinimag.2016.04.010.
33. Lin WC, Muglia VF, Silva GE, Chodraui Filho S, Reis RB, Westphalen AC. Multiparametric MRI of the prostate: diagnostic performance and interreader agreement of two scoring systems. *Br J Radiol.* 2016 Jun;89(1062):20151056. doi: 10.1259/bjr.20151056.
34. Park SY, Jung DC, Oh YT, Cho NH, Choi YD, Rha KH, et al. Prostate Cancer: PI-RADS Version 2 Helps Preoperatively Predict Clinically Significant Cancers. *Radiology.* 2016 Jul;280(1):108-16. doi: 10.1148/radiol.16151133.
35. Ahmed HU, El-Shater Bosaily A, Brown LC, Gabe R, Kaplan R, Parmar MK, et al.; PROMIS study group. Diagnostic accuracy of multi-parametric MRI and TRUS biopsy in prostate cancer (PROMIS): a paired validating confirmatory study. *Lancet.* 2017 Feb 25;389(10071):815-22. doi: 10.1016/S0140-6736(16)32401-1.
36. Sheridan TB, Carter HB, Wang W, Landis PB, Epstein JI. Change in prostate cancer grade over time in men followed expectantly for stage T1c disease. *J Urol.* 2008 Mar;179(3):901-4; discussion 904-5. doi: 10.1016/j.juro.2007.10.062.
37. Valerio M, Anele C, Charman SC, van der Meulen J, Freeman A, Jameson C, et al. Transperineal template prostate-mapping biopsies: an evaluation of different protocols in the detection of clinically significant prostate cancer. *BJU Int.* 2016 Sep;118(3):384-90. doi: 10.1111/bju.13306.

## Sažetak

## EVALUACIJA DIJAGNOSTIČKE TOČNOSTI DRUGE VERZIJE SUSTAVA ZA RADIOLOŠKU KLASIFIKACIJU PROMJENA U PROSTATI (PI-RADS V2) ZA DETEKCIJU KARCINOMA PROSTATE: RETROSPEKTIVNA STUDIJA JEDNE USTANOVE

L. Grbanović, L. Kovačević, T. Kuliš, Ž. Kaštelan, M. Kralik, S. Ivandić i M. Prutki

Cilj ovog istraživanja je procijeniti točnost multiparametrijske magnetske rezonancije (mpMR) prostate interpretirane uz pomoć druge verzije sustava za radiološku klasifikaciju promjena u prostati (PI-RADS v2) u detekciji klinički značajnih karcinoma prostate (csPCa).

Učinjena je retrospektivna analiza 62 bolesnika kojima je između siječnja i prosinca 2018. godine zbog sumnje na postojanje karcinoma prostate snimljen mpMR prostate interpretiran prema PI-RADS v2.

Patohistološka analiza korištena je kao referentni standard u bolesnika kojima je na taj način potvrđen csPCa, a u bolesnika s negativnim ili nedostupnim patohistološkim nalazima praćenjem od barem četiri godine isključeno je postojanje csPCa.

Mjere dijagnostičke točnosti mpMRI prostate za detekciju csPCa izračunate su korištenjem graničnih vrijednosti PI-RADS kategorija 3 i 4. Od ukupno 114 mpMR pregledom detektiranih lezija, 21 je identificirana kao csPCa. Stope detekcije csPCa za PI-RADS kategorije, redom od 1 do 5, bile su 0%, 5.1%, 8.3%, 47.1%, i 87.5%. Granična vrijednost PI-RADS 4 pokazala je bolju specifičnost (83.9%) i pozitivnu prediktivnu vrijednost (93%) u odnosu na PI-RADS 3 (specifičnost 41.9%; pozitivna prediktivna vrijednost 26%) uz nižu osjetljivost (71.4% u usporedbi s 90.5%), čime smo previdjeli 28,6% csPCa.

Zaključno, za bolju detekciju csPCa važno je uključiti PI-RADS 3 lezije, premda to dovodi do manje specifičnosti i nepotrebnih biopsija.

Ključne riječi: *karcinom prostate, multiparametrijska magnetska rezonancija prostate, PI-RADS.*